



## PATIENT

Petey Kantor

## SPECIES

Feline

## BREED

Himalayan

## SEX

Male

## AGE

17 years

## WEIGHT

9.6lbs

## INTERPRETED BY

Maggie Machen Lamy,  
DVM, DACVIM  
(Cardiology)

## IMAGING PERFORMED BY

Jennifer Snyder

## HOSPITAL NAME

Sands Hill Mobile  
Veterinary Ultrasound

## REFERRING VET

Dr. Tarter

## INVOICE

22311

## DATE

12/7/21

## PRESENTING CLINICAL SIGNS

History: Heart murmur, Occasional gallop. Bloodwork WNL. Assess prior to dental.

## ECHOCARDIOGRAM FINDINGS

2D, m-mode, color flow and doppler imaging is available. The left ventricular wall is borderline normal in dimension with regions of irregularity. There is a diffusely hyperechoic endocardium consistent with fibrosis and remodeling. Papillary muscles appear mildly hypertrophied. The anterior leaflet of the MV appears normal. The left atrium is normal in size. The right atrium is normal in size. The right ventricle appears normal. No TR. The mitral valve is normal in structure and mobility. Blood flow through the RVOT is normal in velocity. Blood flow through the LVOT is mildly elevated depending on heart rate with a dynamic profile. Trace eccentric mitral regurgitation. There is no pleural or pericardial effusion seen. There are no obvious cardiac tumors.

## CARDIAC CHART

FELINE CARDIAC PARAMETERS	BODY WEIGHT (kg)	HR (BPM)	IVSd (cm) (Moise, Pipers)	LVIDd (cm) (Moise, Pipers)	LWVd (cm) (Moise, Pipers)	FS (%)	EF (%)
NORMAL PARAMETER	-----	150-240	0.35-0.55	<2 (mean 1.5)	3.5-0.55	35-67	80-100
PATIENT	4.4	210	0.56	1.35	0.56	56	89
FELINE CARDIAC PARAMETERS	LA/AO (Boon)	LA/AO HEART BASE (Swe) (Abbott)	LA 2D short axis Base view (cm) (Abbott)		LVOT VEL (m/s)	RVOT VEL (m/s)	E max (m/s)
NORMAL	<1.5	<1.3	<1.2		<1.6	<1.3	<0.9
PATIENT	1.3	1.2	1.26		2.2	0.74	NM

*\*Note: All measurements based upon multi-modal images and methods. An average value is reported.  
Adapted from June Boon, Veterinary Echocardiography, 1998  
Abbott J & MacLean H JVIM 2006;20: 111-119, Moise et al. Am J Vet Res 47:1476, 1986. Pipers et al. Am J Vet Res 40:882, 1979.*

## INTERPRETATION OF THE FINDINGS & FURTHER RECOMMENDATIONS

The cause of the murmur is a dynamic LVOT obstruction, secondary to abnormal valve movement and tachycardia (SAM). The LV wall dimensions are borderline normal however, with no clear hypertrophic component at this time. These findings may represent early HOCM, however there is a subset of cats with a dynamic LVOT obstruction that is stress-related and does not lead to secondary LVH or LA dilation. Serial echocardiography will be necessary to determine progression and clinical relevance of findings. Should LVH develop in the future, a beta blocker may be indicated to lower heart rate and decrease the pressure gradient.

Monitor for any clinical signs associated with progression, including increased RR/RE, syncope or signs of a blood clot (paralysis, neurologic change, etc.).

Anesthetic risk is currently low. Avoid heart rate stimulating drugs (atropine, glycopyrrolate) unless clinically necessary. Avoid vasodilators such as acepromazine as this can worsen obstruction. Judicious IV fluid rates are recommended to avoid fluid overload in this patient with diastolic dysfunction.



**PATIENT**

Petey Kantor

A recheck echocardiogram is recommended in 6-12 months to assess for progression, sooner if any clinical signs arise.

**SPECIES**

Feline

**BREED**

Himalayan

**SEX**

Male

**AGE**

17 years

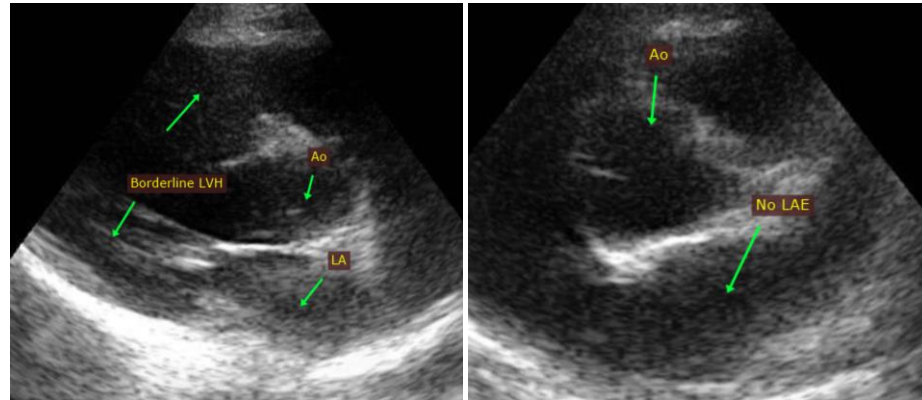
**WEIGHT**

9.6lbs

**INTERPRETED BY**

Maggie Machen Lamy,  
DVM, DACVIM  
(Cardiology)

**IMAGES**



The information and recommendations provided are based on the images presented by the referring veterinarian. No evaluation can be communicated regarding pathology that was not visible in the image/video clips provided.

Thank you for this referral. This report was generated using transcription software, and minor dictation errors may be present. If the clinical or image interpretation does not parallel your findings or if I can be of any further assistance, please contact me.

**Maggie Machen Lamy, DVM**  
Diplomate of the American College of Veterinary Internal Medicine (Cardiology)  
info@sonopath.com

**IMAGING PERFORMED BY**

Jennifer Snyder

**HOSPITAL NAME**

Sands Hill Mobile  
Veterinary Ultrasound

**REFERRING VET**

Dr. Tarter

**INVOICE**

22311

**DATE**

12/7/21